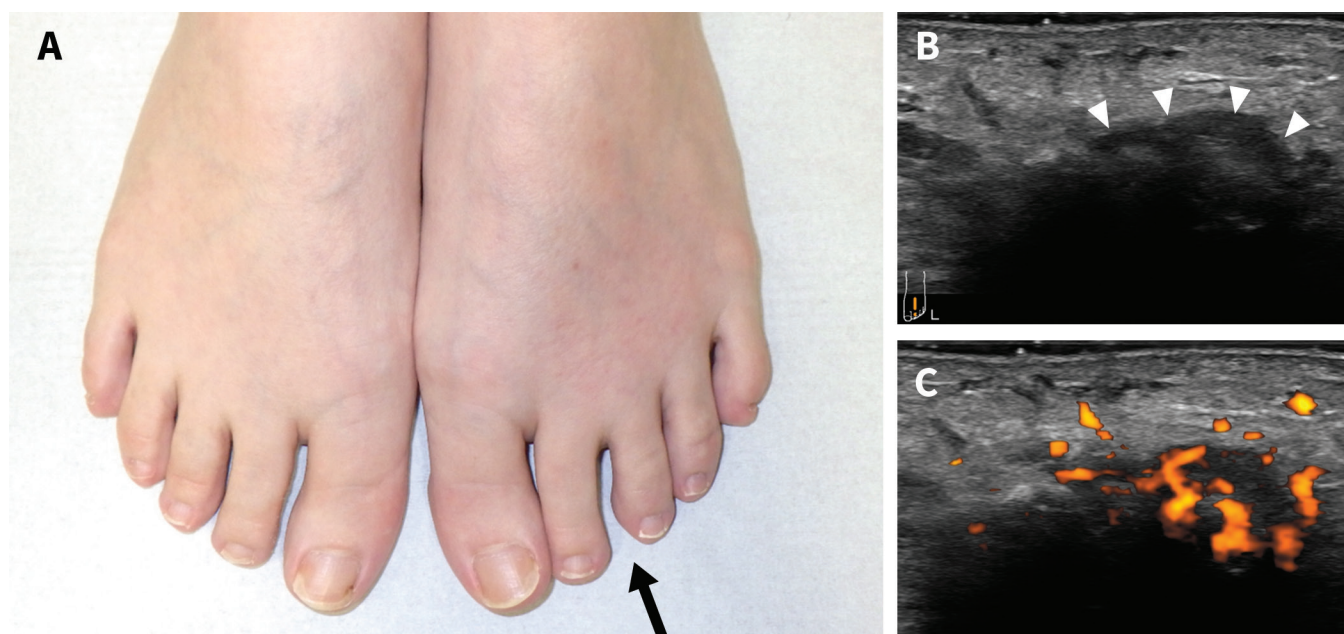


# Separating toes due to intermetatarsal bursitis in rheumatoid arthritis

Eisuke Takamasu MD, Yuji Miyoshi MD

■ Cite as: *CMAJ* 2023 December 11;195:E1661-2. doi: 10.1503/cmaj.231253



**Figure 1:** (A) A 42-year-old woman's forefeet showing separating toes, with widening of the interdigital space between the second and third toes in the left forefoot (black arrow) compared with the asymptomatic contralateral side. In (B) and (C), ultrasonography using a dorsal longitudinal scan between the left second and third metatarsophalangeal joints showed a round-shaped, power Doppler-positive, hypoechoic structure (white arrowheads), suggestive of intermetatarsal bursitis. The right side of the images from ultrasonography is distal and the left side is proximal.

A 42-year-old woman presented to our outpatient clinic with a 6-week history of pain in her right fingers and left forefoot. Physical examination revealed swelling and tenderness of the right third metacarpophalangeal and proximal interphalangeal joints. She had pain and swelling at the left second intermetatarsal space, with widening of the interdigital space separating the second and third toes (Figure 1A). Laboratory tests were positive for rheumatoid factor and cyclic citrullinated peptide antibody (anti-CCP) but acute phase reactants were normal. In a longitudinal scan of the left second intermetatarsal space, ultrasonography showed a hypoechoic, Doppler-positive structure (Figure 1B and 1C). None of the metatarsophalangeal joints of the left foot showed findings of synovitis. We diagnosed rheumatoid arthritis with intermetatarsal bursitis (IMB), and treated her with methotrexate, salazosulfapyridine and, in the

short-term, a nonsteroidal anti-inflammatory drug. Three months after starting the treatment, the patient's symptoms, including forefoot pain, resolved.

Intermetatarsal bursitis refers to the inflammation of the bursas found between the metatarsal heads located on the dorsal side of the deep transverse metatarsal ligament (Appendix 1, available at [www.cmaj.ca/lookup/doi/10.1503/cmaj.231253/tab-related-content](http://www.cmaj.ca/lookup/doi/10.1503/cmaj.231253/tab-related-content)).<sup>1</sup> The differential diagnosis of patients with metatarsalgia and toes spreading includes Morton neuroma, IMB and rheumatoid nodules, in addition to traumatic and degenerative foot deformity.<sup>2</sup> Ultrasonography of IMB shows a characteristic hypoechoic, Doppler-positive structure between the metatarsal heads, as seen in our patient. The presence of IMB is significantly associated with anti-CCP and rheumatoid factor positivity among patients with rheumatoid arthritis;<sup>3</sup> IMB is also

reported as a useful diagnostic finding for rheumatoid arthritis with reasonable sensitivity (69%) and specificity (70%).<sup>1</sup> Metatarsalgia with widened interdigital space separating 2 adjacent toes in patients with suspected inflammatory arthritides, can indicate the presence of IMB, suggestive of rheumatoid arthritis.

## References

1. Larsen SB, Søgaard SB, Nielsen MB, et al. Diagnostic considerations of intermetatarsal bursitis: a systematic review. *Diagnostics (Basel)* 2023;13:211.
2. Chaganti S, Joshy S, Hariharan K, et al. Rheumatoid nodule presenting as Morton's neuroma. *J Orthop Traumatol* 2013;14:219-22.
3. Hammer HB, Kvien TK, Terslev L. Intermetatarsal bursitis is frequent in patients with established rheumatoid arthritis and is associated with anti-cyclic citrullinated peptide and rheumatoid factor. *RMD Open* 2019;5:e001076. doi: 10.1136/rmdopen-2019-001076.

**Competing interests:** None declared.

This article has been peer reviewed.

The authors have obtained patient consent.

**Affiliation:** Department of Rheumatic Diseases, Tokyo Metropolitan Tama Medical Center, Tokyo, Japan.

**Content licence:** This is an Open Access article distributed in accordance with the terms of the Creative Commons Attribution (CC BY-NC-ND 4.0) licence, which permits use, distribution and reproduction in any medium, provided that the original publication is properly cited, the use is noncommercial (i.e., research or educational use), and no modifications or adaptations are made. See: <https://creativecommons.org/licenses/by-nc-nd/4.0/>

**Correspondence to:** Eisuke Takamasu, e.t.masuo.369@gmail.com

Clinical images are chosen because they are particularly intriguing, classic or dramatic. Submissions of clear, appropriately labelled high-resolution images must be accompanied by a figure caption. A brief explanation (300 words maximum) of the educational importance of the images with minimal references is required. The patient's written consent for publication must be obtained before submission.