

# Acute food impaction in an adult with previously undiagnosed eosinophilic esophagitis

Hiral S. Patel MD, Merin Reji MD, Guha Krishnaswamy MD

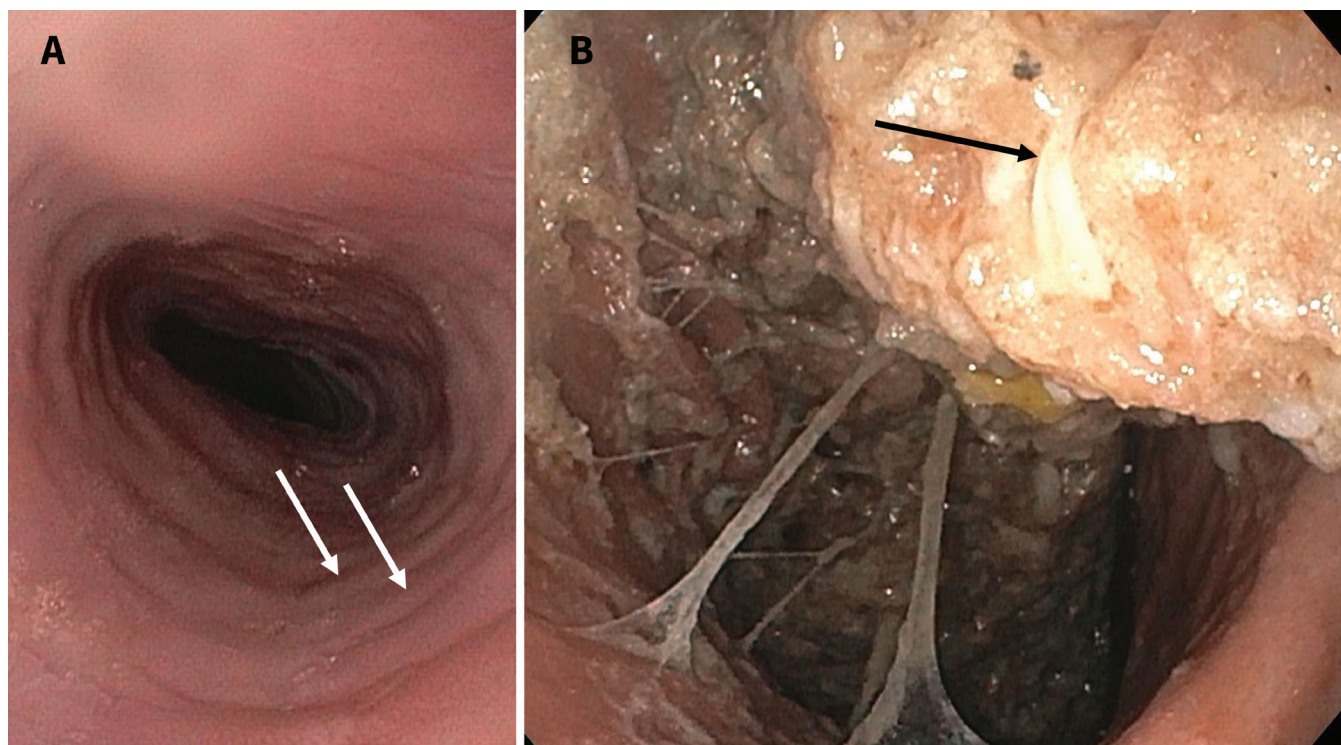
■ Cite as: *CMAJ* 2023 February 13;195:E234-5. doi: 10.1503/cmaj.221054

A 31-year-old man with a history of allergic rhinitis, asthma and eczema presented to the emergency department with sudden dysphagia and food impaction while eating steak. He reported intermittent dysphagia and gastroesophageal reflux over several months despite proton pump inhibitor therapy. We diagnosed “steakhouse syndrome,” or esophageal food impaction. The gastroenterology team performed urgent esophagogastroduodenoscopy, which showed furrowing and concentric rings, consistent with eosinophilic esophagitis (Figure 1A).<sup>1</sup> They extracted the impacted food endoscopically (Figure 1B). Esophageal biopsy showed eosinophilic esophagitis. We prescribed pantoprazole 40 mg twice daily and fluticasone propionate 440 µg twice daily (swallowed, not inhaled). He has since required periodic dilatation of strictures.

Food impaction in the esophagus occurs in 25 people per 100 000 per year.<sup>2</sup> Beef, chicken, pork, poorly cooked vegetables

and rice have been most frequently incriminated. Eosinophilic esophagitis is a common cause of food impaction seen in the emergency department; others are esophageal stenosis, malignant disease, hiatal hernia and dysmotility.<sup>2</sup> Strictures develop in 17%–70% of patients, depending on delays in diagnosis. Esophageal dysmotility and fibrostenosis cause food bolus obstruction, which, if left untreated, can lead to dehydration, pulmonary aspiration and esophageal perforation within 24 hours.<sup>3</sup>

Esophageal eosinophilia ( $\geq 15$  eosinophils per high power field) and exclusion of other potential causes of tissue eosinophilia (proton pump inhibitor therapy, Crohn disease, malignant disease, autoimmunity, drug hypersensitivity and parasitic disease) and endoscopy help confirm eosinophilic esophagitis.<sup>4</sup> Patients are asked to swallow (not inhale) fluticasone (440–880 µg twice daily), avoiding food or drink for 30 minutes afterward.<sup>5</sup>



**Figure 1:** Esophagogastroduodenoscopy images from a 31-year-old man with acute food impaction, showing (A) concentric ring formation or felonization (white arrows), a typical finding of eosinophilic esophagitis, and (B) an impacted piece of steak (black arrow) at 30 cm.

Budesonide for nebulizer use can be administered as a slurry mixed with a flavoured sugar substitute (off-label use). Dupilumab, an antibody to interleukin-4, has recently received approval from the United States Food and Drug Administration for patients with refractory eosinophilic esophagitis, but its use is limited by availability and cost. Impacted food may require endoscopic extraction, while strictures may require dilatation.

## References

1. Stadler J, Hölscher AH, Feussner H, et al. The “steakhouse syndrome.” Primary and definitive diagnosis and therapy. *Surg Endosc* 1989;3:195-8.
2. Gretarsdottir HM, Jonasson JG, Bjornsson ES. Etiology and management of esophageal food impaction: a population-based study. *Scand J Gastroenterol* 2015;50:513-8.
3. Hardman J, Sharma N, Smith J, et al. Conservative management of oesophageal soft food bolus impaction. *Cochrane Database Syst Rev* 2020;5:CD007352.
4. Dellon ES, Liacouras CA, Molina-Infante J, et al. Updated international consensus diagnostic criteria for eosinophilic esophagitis: proceedings of the AGREE Conference. *Gastroenterology* 2018;155:1022-33.e10.
5. Hirano I, Chan ES, Rank MA, et al. AGA Institute and the Joint Task Force on Allergy-Immunology Practice Parameters Clinical Guidelines for the Management of Eosinophilic Esophagitis. *Gastroenterology* 2020;158:1776-86.

**Competing interests:** Guha Krishnaswamy reports royalties from UpToDate and a previous role as an external consultant for Johns Hopkins University. No other competing interests were declared.

This article has been peer reviewed.

The authors have obtained patient consent.

**Affiliations:** Department of Internal Medicine (Patel, Reji, Krishnaswamy), Wake Forest School of Medicine; Department of Medicine (Krishnaswamy), Division of Allergy, Immunology and Pulmonary, and Division of Infectious Disease, Wake Forest School of Medicine, Winston-Salem, NC; W.G. (Bill) Hefner Salisbury Department of Veterans Affairs Medical Center and Affiliated Institutions (Krishnaswamy), Salisbury and Kernersville, NC

**Content licence:** This is an Open Access article distributed in accordance with the terms of the Creative Commons Attribution (CC BY-NC-ND 4.0) licence, which permits use, distribution and reproduction in any medium, provided that the original publication is properly cited, the use is noncommercial (i.e., research or educational use), and no modifications or adaptations are made. See: <https://creativecommons.org/licenses/by-nc-nd/4.0/>

**Correspondence to:** Guha Krishnaswamy, [gkrishna@wakehealth.edu](mailto:gkrishna@wakehealth.edu)